

MOUTH CANCER INFORMATION SHEET FOR PHARMACISTS

Signs & symptoms

Mouth (oral) cancer can affect the:

- Tongue
- Lips
- Lining of the cheeks
- Gums
- Floor of the mouth
- Roof of the mouth
- Upper part of the throat
- Tonsils

Potential signs and symptoms

You should advise patients to see a dentist/doctor if they have had these symptoms for three weeks or more.

The most common signs of mouth cancer are:

- An ulcer or sore anywhere in your mouth
- A red or white patch in the mouth
- Unexplained pain in the mouth or ear

Other signs to look out for are:

- An unexplained lump in the neck
- A sore or painful throat
- A croaky voice or difficulty swallowing

These signs and symptoms are especially important if the patient:

- is a smoker or heavy alcohol drinker
- chews betel nut (areca nut) or tobacco
- is over 40 years old

Symptoms may not always be accompanied with pain

Information for Pharmacy staff

Pharmacists and pharmacy assistants will be aware of the types of products that are often prescribed or requested by members of the public to relieve mouth complaints.

Some products may mask the signs and symptoms of mouth cancer. The BNF advises that local analgesics have a limited role in the treatment of oral ulceration.

If patients request products for the treatment of mouth ulcers, it may be appropriate to ask the patient about their complaint and the length of time they have had it.

This is particularly important in the case of repeated requests.

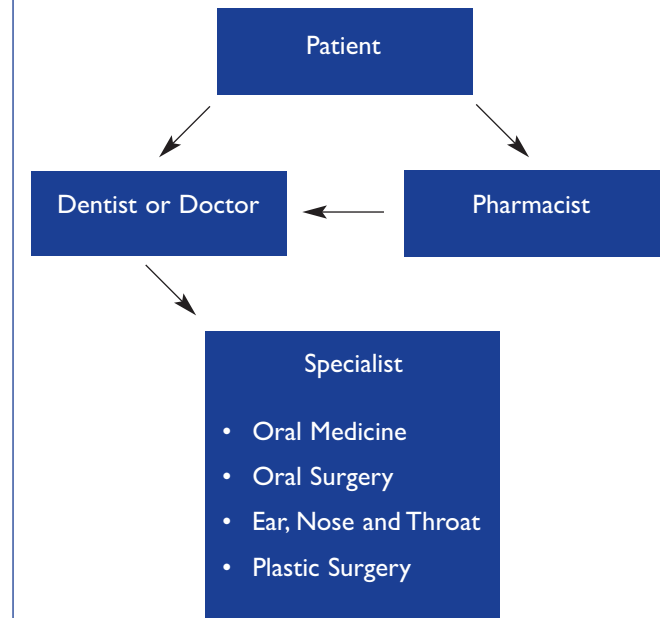
If there are concerns, the pharmacist should advise the person to see their dentist or doctor.

Examples of products that may be requested:

- Adcortyl in orabase
- Betadine
- Bioral
- Bonjela*
- Calgel
- Corlan
- Corsodyl
- Difflam
- Oraldene
- Pyralvex*
- Teejel*

*contains salicylate

Referral Pathway



For more information

Visit www.openuptomouthcancer.org for more information on oral cancer, and Cancer Research UK's **Open Up to Mouth Cancer** campaign.

Produced by Cancer Research UK in consultation with specialists

Photos from Health Scotland and Glasgow Dental Hospital
Nov 2005

Registered charity no.1089464

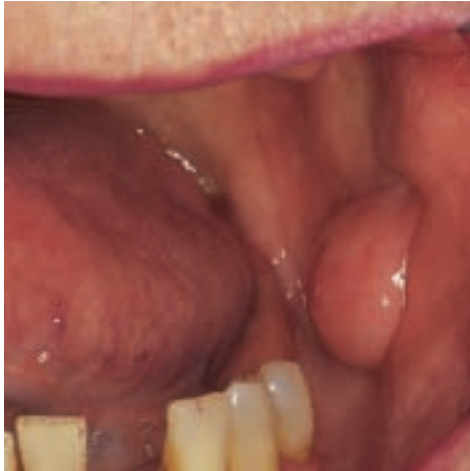

CANCER RESEARCH UK

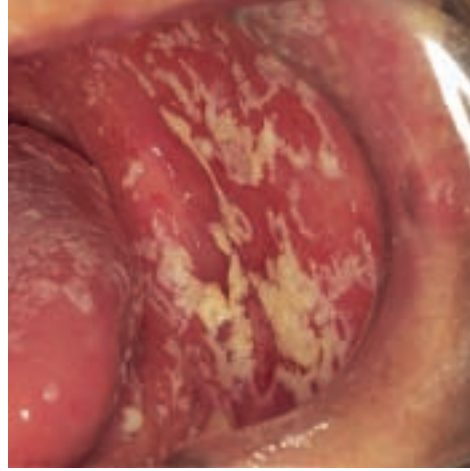


CLINICAL IMAGES OF MOUTH LESIONS

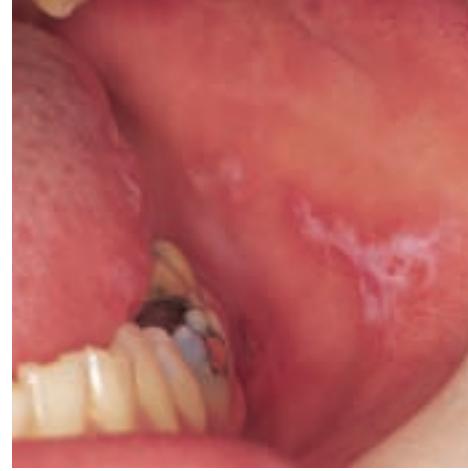Mouth cancer is usually preceded by visible changes in the mouth that can be detected by a quick, visual inspection. Over the page, there is a list of potential signs and symptoms of mouth cancer. But other conditions may present with similar symptoms. Below are examples of some malignant and potentially malignant lesions that you may encounter:



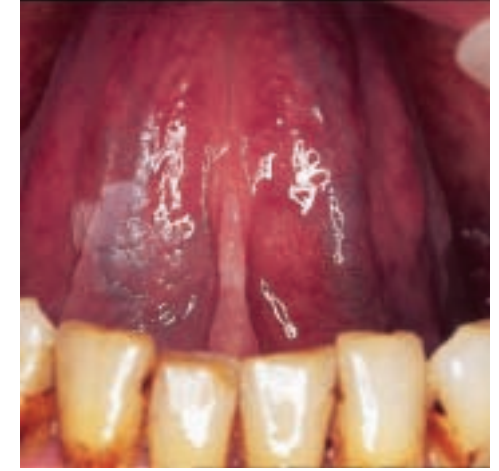Fibroepithelial polyp of the buccal mucosa
Refer to Dentist or Doctor



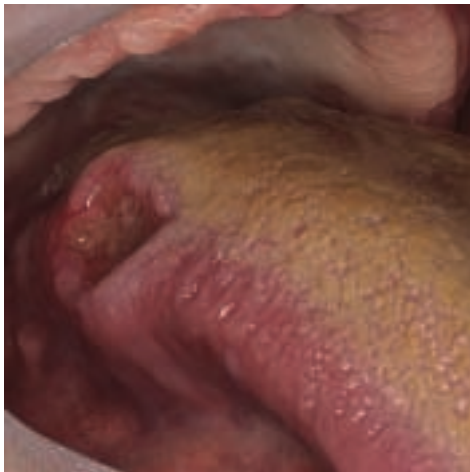Pseudomembranous candidosis of the buccal mucosa
Refer to Dentist or Doctor



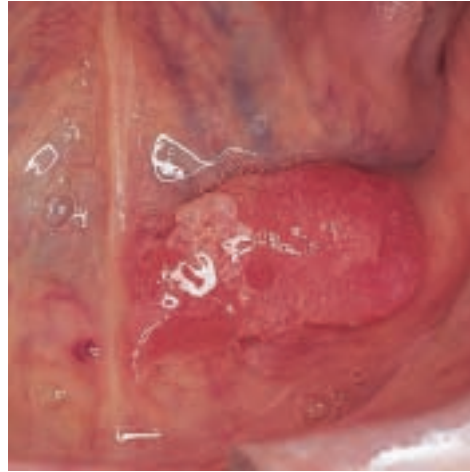Lichen planus of the buccal mucosa
Refer to Dentist or Doctor



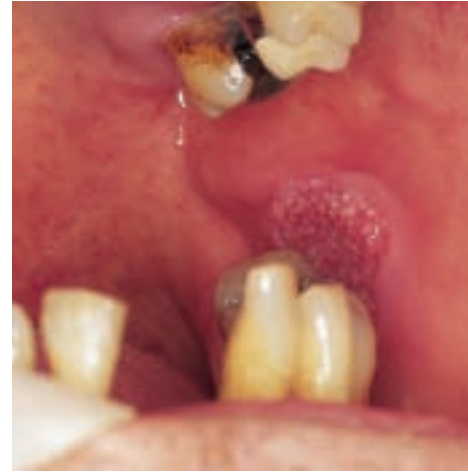White patch on ventral surface of the tongue
Refer to Dentist or Doctor



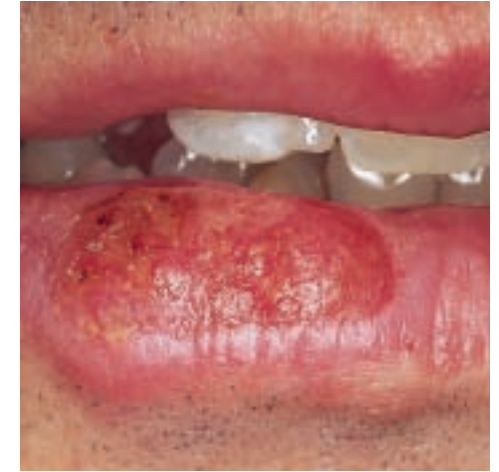Solitary ulcer with rolled borders on the lateral border of the tongue
Refer to Dentist or Doctor



Red patch on ventral surface of tongue and floor of mouth
Refer to Dentist or Doctor



Speckled lesion on left buccal mucosa
Refer to Dentist or Doctor



Shallow ulcer on lower lip
Refer to Dentist or Doctor